SonoPath
Clinical Sonography & Telecytology
EDUCATIONAL TELECONSULTATION SERVICES™
1-800-838-4268 info@sonopath.com SonoPath.com

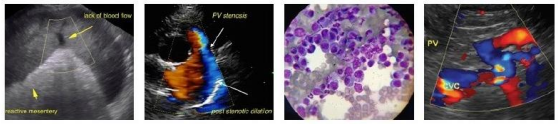

IMAGING PERFORMED BY
pawsonography@gmail.com 530-786-8340

PATIENT
Sadie Cook

SPECIES
Canine

BREED
German SH Pointer

SEX
Female Spayed

AGE
13 years

WEIGHT
50lbs

INTERPRETED BY
Maggie Machen Lamy, DVM, DACVIM (Cardiology)

IMAGING PERFORMED BY
Loetitia St-Jacques, LVT/RVT

HOSPITAL NAME
Tahoe Integrative Care

REFERRING VET
Dr. Robinson

INVOICE
30153

DATE
4/10/23

PRESENTING CLINICAL SIGNS

History: Recheck echo. Grade 2-4/6 heart murmur. Sinus arrhythmia present. Liver mass found during cardiac scan and abdominal ultrasound added.
-Abnormal PE/Chem/CBC/UA Results: ALT 181 ALP 3,330 GGT 365 Reticulocyte Hemoglobin 23.9 Lymphocytes 1.021.
-Pertinent previous echo findings (8/2019 MML): Mild MR without significant LA or LVE, trace TR. LA: 2.7, LV: 4.1.

ELECTROCARDIOGRAPHIC FINDINGS

A six lead ECG is available at 50mm/s; 10mm/mV. The average heart rate is 100bpm (range 44-136bpm). The rhythm is sinus in origin, with a p for every QRS complex and vice versa. The P wave morphology is positive with a normal dimension. Normal PR. The QRS morphology is positive with normal dimension. MEA is normal. No ectopic beats, pauses or dysrhythmias observed.
ECG diagnosis: Profound respiratory sinus arrythmia.

ECHOCARDIOGRAM FINDINGS

2D, m-mode, color flow and doppler imaging is available. Mild diffuse thickening of mitral valve leaflets (anterior> posterior) with minimal prolapse into the left atrial lumen. Mild anterior-directed mitral regurgitation with minimal left atrial dilation. Borderline increased LV diameter with adequate myocardial function. The tricuspid valve appears mildly thickened with septal prolapse and trace tricuspid regurgitation. Normal velocity. Normal right atrial and ventricular diameter and morphology indicating no overt evidence of pulmonary arterial hypertension. The pulmonic and aortic valves are normal in morphology and mobility. Normal pulmonic and aortic outflow velocities. No aortic or pulmonic insufficiency. No pericardial or pleural effusion noted. No cardiac tumors observed.

CARDIAC CHART

CANINE CARDIAC PARAMETERS	MR VMAX (m/s)	TR VMAX (m/s)	LA/AO (Boon method)	LA/AO (Heart Base; Swe)	FS (%)	EF (%)	EPSS (cm)
NORMAL PARAMETER	4.5-5.5	<2.7	1.3	<1.6	28-40	40-100	<0.6
PATIENT	5.4	2.7	NM	1.2	50	92	0.4
CANINE CARDIAC PARAMETERS	**HR** (BPM)	**AV VMAX** (m/s)	**PV MAX** (m/s)	**BODY WEIGHT** (kg)	**LA** 2D short axis Base view (cm)	**LVIDd** Avg; 2D and m-mode short axis (cm)	**LVIDs** Avg; 2D and m-mode short axis (cm)
NORMAL PARAMETER	50-100	0.7-1.7	0.7-1.6	BELOW	BELOW	BELOW	BELOW
PATIENT	NM	1.4	0.8	22.7	2.8	4.2	2.1
*Normal chamber parameters expressed as a mean value (SD)				3	1.27 (5.3)	2.46 (2.46)	1.36 (5.5)
BODY WEIGHT DEPENDENT PARAMETERS				5	1.40 (4.5)	2.74 (5.2)	1.60 (4.7)
**Note: All measurements based upon multi-modal images and methods. An average value is reported.*				10	1.50 (3.8)	3.27 (3.5)	2.06 (3.1)
				15	1.83 (2.0)	3.71 (2.4)	2.43 (2.1)
				20	2.02 (1.9)	4.14 (2.2)	2.80 (2.0)
Adapted from June Boon, Veterinary Echocardiography, 1998				25	2.18 (2.4)	4.48 (2.9)	3.10 (2.5)
Rishniw M and Hollis NE, J Vet Intern Med 2000; 14:429-435				30	2.33 (3.3)	4.83 (3.9)	3.39 (3.4)
Hansson et al, Vet Rad and Ultrasound 2002				35	2.48 (4.3)	5.17 (5.0)	3.69 (4.5)
Bonagura et al. Echocardiography: principles of interpretation, Vet Clin North Am 15:1177, 1995				40	2.62 (5.2)	5.48 (6.1)	3.96 (5.4)
				50	2.88 (7.1)	6.07 (8.3)	4.46 (7.4)

SonoPath
Clinical Sonography & Telecytology
EDUCATIONAL TELECONSULTATION SERVICES™
1-800-838-4268 info@sonopath.com SonoPath.com

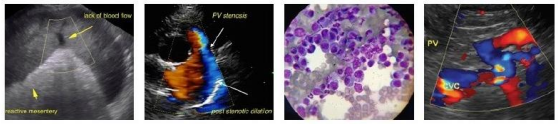

IMAGING PERFORMED BY
pawsonography@gmail.com 530-786-8340

PATIENT
Sadie Cook

SPECIES
Canine

BREED
German SH Pointer

SEX
Female Spayed

AGE
13 years

WEIGHT
50lbs

INTERPRETED BY
Maggie Machen Lamy, DVM, DACVIM (Cardiology)

IMAGING PERFORMED BY
Loetitia St-Jacques, LVT/RVT

HOSPITAL NAME
Tahoe Integrative Care

REFERRING VET
Dr. Robinson

INVOICE
30153

DATE
4/10/23

INTERPRETATION OF THE FINDINGS & FURTHER RECOMMENDATIONS

Compared to the prior study, findings are remarkably similar. Mild MR and trace TR are unchanged without progressive left or right heart enlargement. No additional issues are identified.

The ECG is most consistent with a respiratory sinus arrythmia due to high vagal tone. If there is any question on response to exercise or light stress, an atropine challenge can be administered, particularly if the patient is undergoing anesthesia.

Given these findings, no cardiac medications remain indicated at this time. Monitor for development of a worsening murmur, cough, labored breathing, exercise intolerance or collapse episodes. Omega fatty acid supplementation may be of some long-term benefit.

Anesthetic risk remains mild. Premedicate with a vagolytic and ensure a normal response prior to proceeding. Cardiac protective drug choices (opioid/benzodiazepine premedication, propofol or alfaxalone induction, isoflurane gas) are recommended. Pre-oxygenate for 5-10 minutes prior to induction. Monitor for arrhythmias, hypotension, and hypoxia both intra and post-operatively and intervene as necessary. Mild IV fluid restriction is recommended to avoid fluid overload.

Recommend recheck echocardiogram in 1 year to screen for progression, sooner if any development of clinical signs.

IMAGES

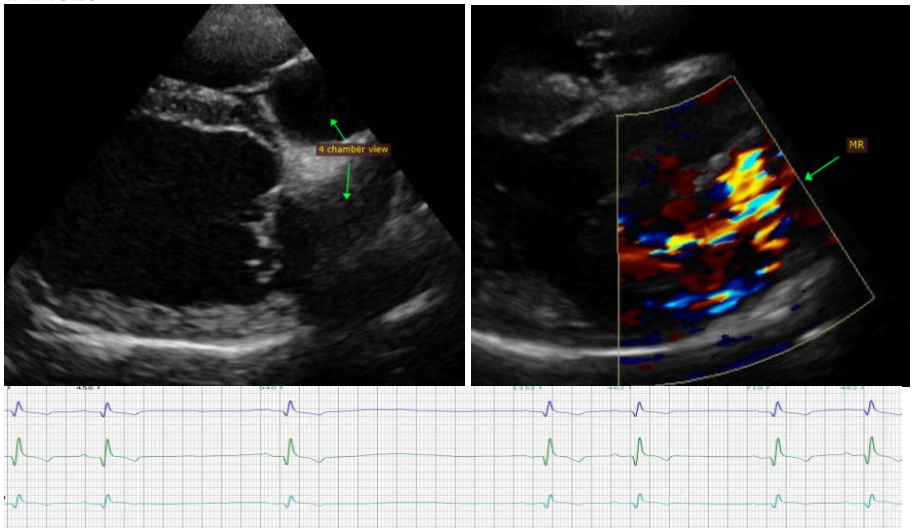

The information and recommendations provided are based on the images presented by the referring veterinarian. No evaluation can be communicated regarding pathology that was not visible in the image/video clips provided.

Thank you for this referral. This report was generated using transcription software, and minor dictation errors may be present. If the clinical or image interpretation does not parallel your findings or if I can be of any further assistance, please contact me.

Maggie Machen Lamy, DVM
Diplomate of the American College of Veterinary Internal Medicine (Cardiology)
info@sonopath.com